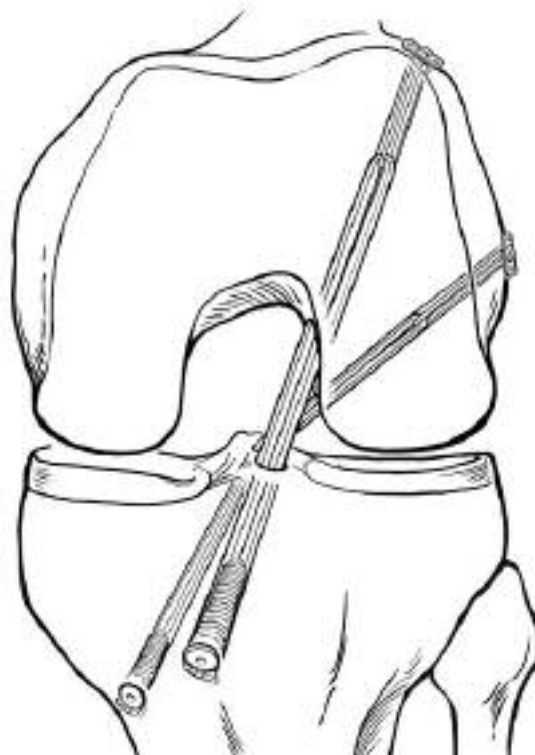

Double Bundle ACL Reconstruction using the Smith & Nephew ENDOBUTTON[◇] CL Fixation System

Freddie H. Fu, MD
Anikar Chhabra, MD
Boris Zelle, MD



Freddie H. Fu, MD

Anikar Chhabra, MD

Boris Zelle, MD

Department of Orthopaedic Surgery,
Center for Sports Medicine
University of Pittsburgh Medical Center
Pittsburgh, PA, USA

Double Bundle ACL Reconstruction using the Smith & Nephew ENDOBUTTON® CL Fixation System

Introduction

The anterior cruciate ligament consists of two functional bundles, the anteromedial and the posterolateral. Anterior cruciate ligament reconstruction has traditionally focused on recreating the anteromedial bundle, while the reconstruction of the posterolateral bundle has not routinely been addressed.

This technique guide presents an arthroscopic anterior cruciate ligament reconstruction that restores both the anteromedial and the posterolateral bundle using either semitendinosus and gracilis autografts or tibialis anterior allografts.

The Double Bundle ACL Reconstruction technique represents a novel approach to restoring the anteromedial and the posterolateral bundles at their anatomic insertion sites on both the tibia and the femur through separate bone tunnels.

We believe that our double bundle anatomic anterior cruciate ligament reconstruction closely reapproximates the native insertion sites of the anterior cruciate ligament on the tibia and the femur, thereby more closely recreating the biomechanical function of the native ligament.

Patient Preparation

Place the patient supine on the operating room table with the nonoperative limb positioned in a well-leg holder in a flexed and abducted position. Apply a pneumatic tourniquet to the operative leg after the limb is exsanguinated. Once the tourniquet is inflated, place the leg into the arthroscopic leg holder and lock it into position. Prep and drape the leg in normal sterile fashion. Identify and mark the tibial tubercle, the patella, the medial and lateral borders of the patellar tendon, and the medial and lateral joint lines.

Graft Harvesting & Preparation

Make a 4 cm skin incision over the anteromedial surface of the tibia, at the level of the tibial tubercle midway between the tubercle and the posteromedial border of the tibia. This incision is used for the harvesting and passage of the grafts as well as the creation of the tibial tunnels.

Note: In order to maintain the morphometric ratio of the AM (anteromedial) and PL (posterolateral) bundles, the AM graft is generally made slightly larger than the PL graft. An 8–9 mm graft for the AM bundle and a 7–8 mm graft for the PL bundle (Figure 1) is suggested.

For the double bundle technique, a minimal graft length of 26 cm for the gracilis and 28 cm for the semitendinosus tendon are recommended for quadruple preparation. Fashion the tendons individually into two quadruple stranded grafts with minimal lengths of 13 and 14 cm. Cut each tendon in two equal tendon halves. Temporarily loop each half over a suture loop to determine the diameter of the quadrupled graft.

In essence, there are eight hamstring bundles crossing the knee joint for the anatomic reconstruction. If the diameter of the two quadrupled grafts appears too thick, or if the gracilis is of insufficient length (<26 cm), then the graft preparation procedure is modified: a double looped gracilis tendon may be used to recreate the PL bundle. Alternatively, double-looped tibialis anterior allografts with a minimal length of 12 cm may be used for each bundle.

Portal Establishment

Establish standard AL (anterolateral) and AM (anteromedial) arthroscopic portals. For ACL Double Bundle reconstruction surgery, place these portals immediately adjacent to the lateral and medial patella tendon borders at the level of the inferior pole of the patella. In addition to the traditional portals, establish an accessory AM portal just above the medial meniscus using an 18-gauge needle under direct visualization (Figure 2). This portal is more medial and inferior in its placement and is used for the identification and drilling of the PL femoral tunnel. The placement of this accessory AM portal is critical in obtaining the correct trajectory and entry point for the PL femoral tunnel (Figure 3).

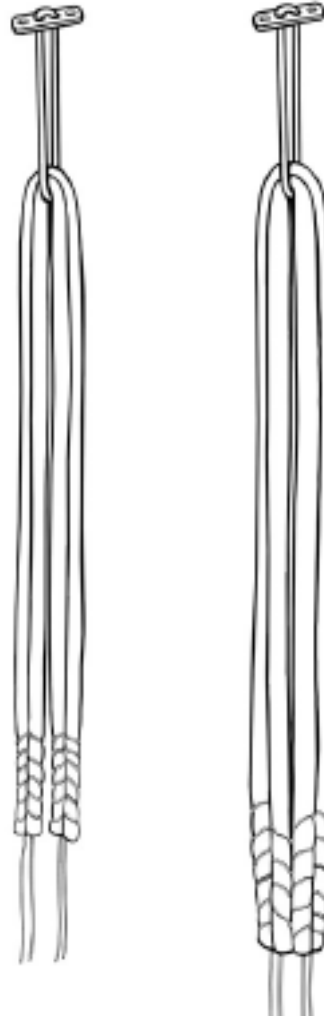


Figure 1

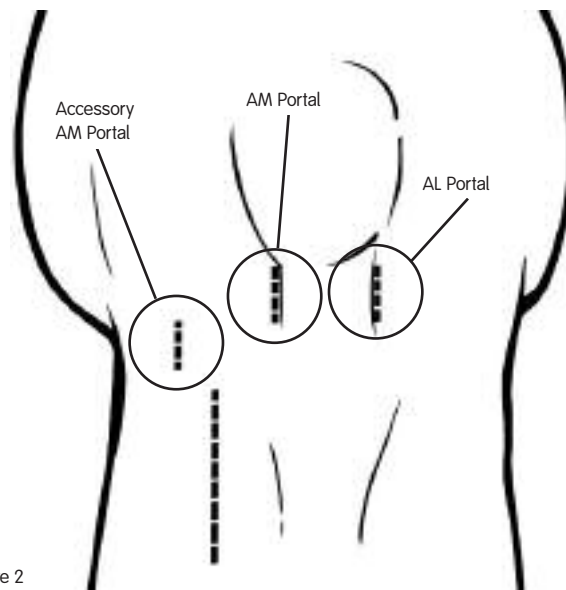


Figure 2

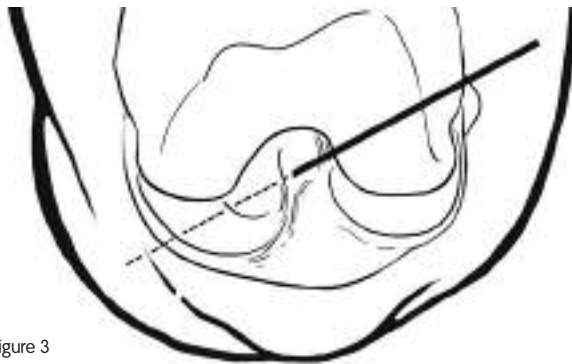

Figure 3

Perform a complete diagnostic arthroscopy and address any intraarticular pathology (i.e., meniscal or chondral injury) at this time. Leave the tibial footprint of the ACL intact for its proprioceptive and vascular contributions. Identify the anatomic footprints of the AM and PL bundles of the ACL on the lateral wall of the intercondylar notch. When introducing the arthroscope into the AM and AL portals in combination, the three-dimensional visualization of the ACL femoral footprint on the wall of the intercondylar notch is enhanced when compared to the view from a single portal.

Drill the PL Femoral Tunnel

Drill the PL femoral tunnel first using the accessory AM portal. Place the arthroscope into the AM portal to allow a direct view of the PL femoral origin.

Using an endoscopic femoral aimer, pass a 2.7 mm passing pin into the posterior and distal portion of the lateral notch of the femur (Figure 4). Place the guide wire adjacent to the medial femoral condyle articular surface and just above the medial meniscus.

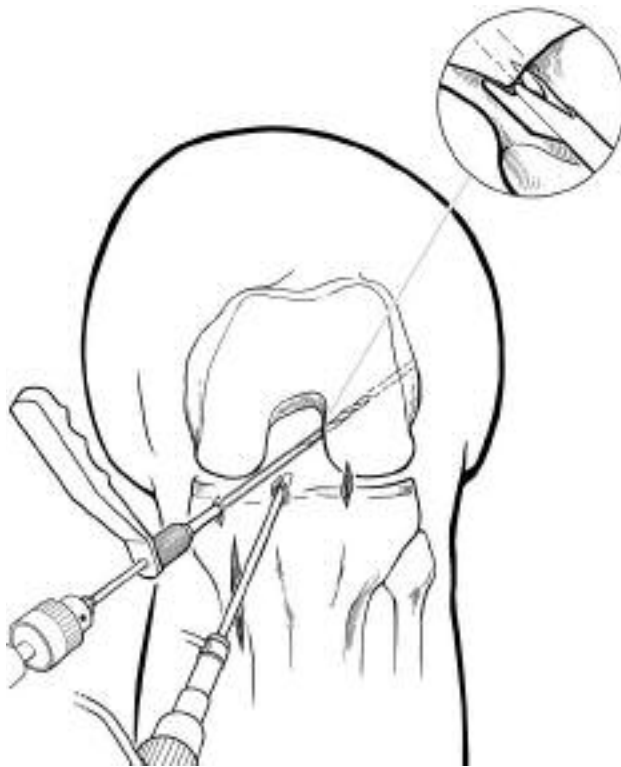

Figure 4

Caution: adequate distance is needed to ensure the drill will not violate either of these surfaces; visualization from the medial infrapatellar portal may help avoid injury to the chondral surface.

Flex the knee to approximately 110° so that the guide wire exits the lateral thigh in an anterior orientation, preventing injury to the peroneal nerve.

Once the guide wire is in an acceptable position, drill the tunnel with an acorn drill over the guide wire to a depth of approximately 25–30 mm. Drill the tunnel to a diameter that is 1 mm smaller than the actual diameter of the PL graft and expand it to the desired size using serial dilators in 0.5 mm increments. Breach the far cortex with a 4.5 mm ENDOBUTTON Drill and use the ENDOBUTTON Depth Gauge to assess the distance to the far cortex. This tunnel typically requires an ENDOBUTTON Loop of approximately 15–20 mm.

Drill the PL and AM Tibial tunnels

Drill the tibial tunnel for the PL bundle first and the AM tunnel second. Place the Smith & Nephew ACUFEX® ACL Tibial Drill Guide on the PL aspect of the ACL tibial footprint with the angle set to 55° (Figure 5). This tunnel has a more medial and distal starting point on the tibial cortex than a standard ACL tibial tunnel. This position is typically just anterior to the superficial medial collateral ligament fibers (Figure 6).

Once acceptable placement of the PL tibial guide wire is obtained, place the AM tibial guide wire. Reset the drill guide to 45°. The guide wire for the tunnel of the AM bundle is positioned in a more anteromedial position on the tibial footprint (Figure 6). The starting point of the AM guide wire on the tibial cortex is more proximal and central than the PL guide wire. An osseous bridge of approximately 1–2 cm should remain on the tibial cortex between the two tunnels (Figure 7).

Drill the PL tibial tunnel to a diameter of 1 mm less than the diameter of the PL graft. Expand the tunnel with serial dilators. Drill the AM tibial tunnel to a diameter of 1 mm less than the diameter of the AM graft. Expand the tunnel with serial dilators. Place the dilators into the tibial footprint and observe within the joint to assure that the grafts will pass concomitantly.

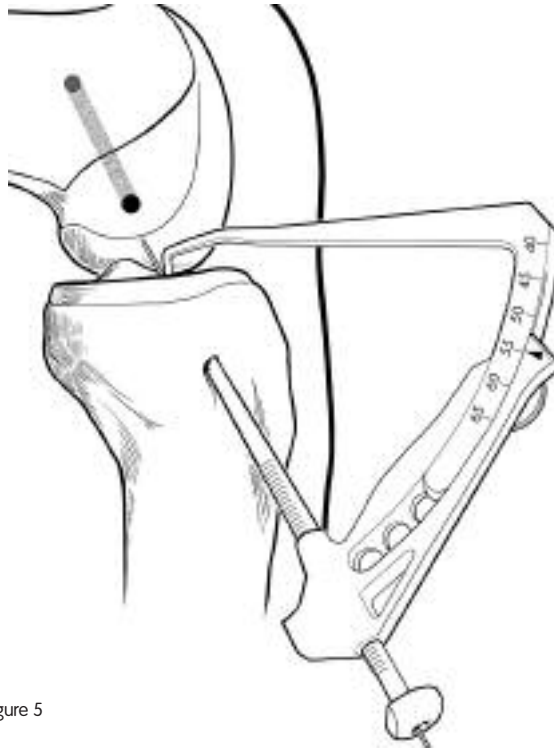


Figure 5

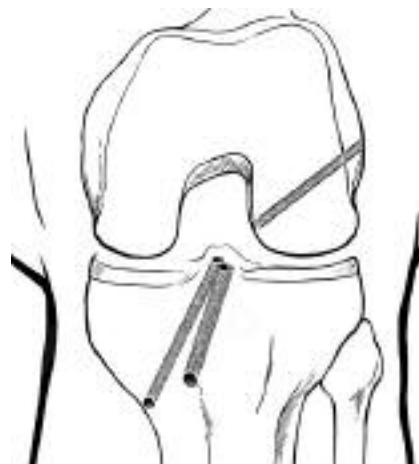

Figure 6

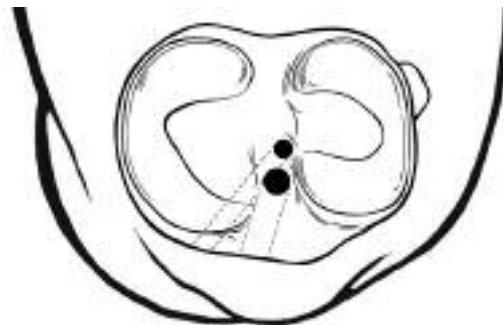


Figure 7

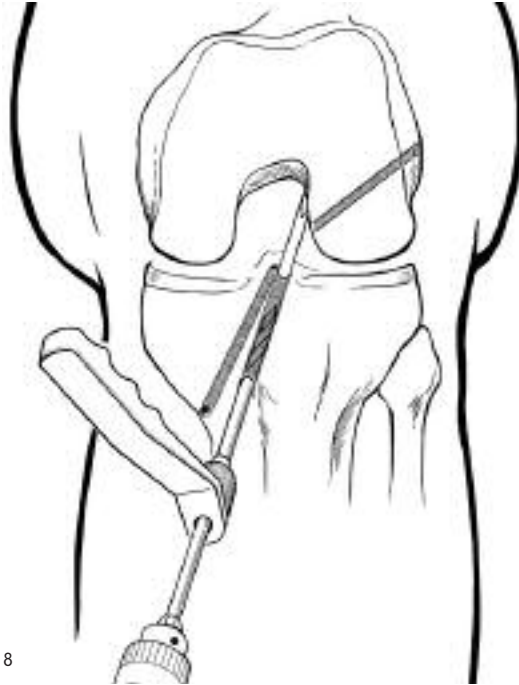

Figure 8

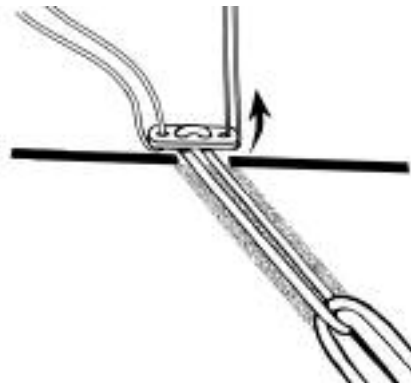


Figure 9

Drill the AM Femoral tunnel

The AM femoral tunnel is the last tunnel drilled. A transtibial technique is used in the same fashion that a single bundle reconstruction would be performed. Place a 6 or 7 mm over-the-top guide on the posterior cortex of the notch between the 10:30 and 11:00 o'clock positions (Figure 8). Pass a guide wire to a depth of 10–15 mm, and drill the tunnel over the guide wire to a depth of 30–35 mm.

Drill the tunnel to a diameter that is 1 mm less than the diameter of the PL graft. Expand the tunnel with serial dilators. Breach the far cortex with the ENDOBUTTON Drill and use the ENDOBUTTON Depth Gauge to assess the distance to the far cortex. This tunnel usually requires a longer ENDOBUTTON Loop of approximately 30–40 mm.

Final Graft Preparation and Insertion

Once the tunnel lengths are determined, final graft preparation is completed. Each allograft is doubled over a continuous loop ENDOBUTTON device of appropriate length (Figure 1). Ideally at least 20–30 mm of the tendon graft rests within each respective femoral tunnel.

Pass the graft for the PL bundle first. Attach a #5 polyester braided suture to one outside hole of the ENDOBUTTON device to lead and pass the device. Attach a trailing #2 polyester braided suture to the opposite outside hole of the ENDOBUTTON device to rotate, or “flip”, the ENDOBUTTON device as it exits the AL femoral cortex (Figure 9).

Pass the beath pin with a long looped suture attached to the eyelet through the accessory AM portal and out through the PL femoral tunnel, piercing the quadriceps and skin proximally.

Caution: flex the knee to approximately 110° to ensure that the beath pin exits anterior to the biceps femoris, thus protecting the peroneal nerve.

Visualize the looped suture within the joint and retrieve it through the PL tibial tunnel using an arthroscopic suture grasper. Attach the long looped suture to the ENDOBUTTON/graft complex, ensuring the #5 suture is pulled first, and advance the PL graft into the femoral tunnel until the ENDOBUTTON device has cleared the femoral cortex.

Pull the trailing #2 suture to rotate, or “flip”, the ENDOBUTTON device immediately external to the femur. Hold the ENDOBUTTON device perpendicular to the femoral cortex and pull back on the graft, locking the ENDOBUTTON device on the outer femoral cortex.

The trajectory of the PL femoral tunnel is primarily through metaphyseal bone. If there is any concern regarding the quality of the bone or the strength of the metaphyseal cortex, supplement the femoral fixation of the PL bundle with a 6 mm Smith & Nephew CALAXO® bioabsorbable interference screw.

Pass the graft for the AM bundle in a standard fashion using a transtibial technique via a beath pin with a loaded looped suture (Figure 10). Flip the ENDOBUTTON device and test the fixation.

Cycle the knee through a full range of motion from 0° to 120° approximately 20–30 times. Apply tension and fix the PL bundle first while the knee is in 15° of flexion, followed by the AM bundle at 75° of flexion. Use bioabsorbable screws that are the same diameter as the corresponding tunnel for tibial fixation (Figure 11).

A single staple is typically used as adjunctive fixation on the tibial side. Cycle the knee through a final full range of motion and examine the graft arthroscopically to exclude graft impingement.

If correct placement of the tunnels was achieved, almost the entire PL bundle will be hidden behind the AM bundle and will be seen “peaking” out from behind the AM graft (Figure 12).

Postoperative Care

Postoperatively the patient is placed in a hinged knee brace. Full weight bearing is allowed with the knee locked in extension. CPM is started immediately from 0°–45° of flexion, and increased by 10° per day. The brace is unlocked at 1 week, and crutches are maintained until quadriceps control is reestablished: – typically about 4–6 weeks. Follow standard ACL reconstruction rehabilitation protocols.

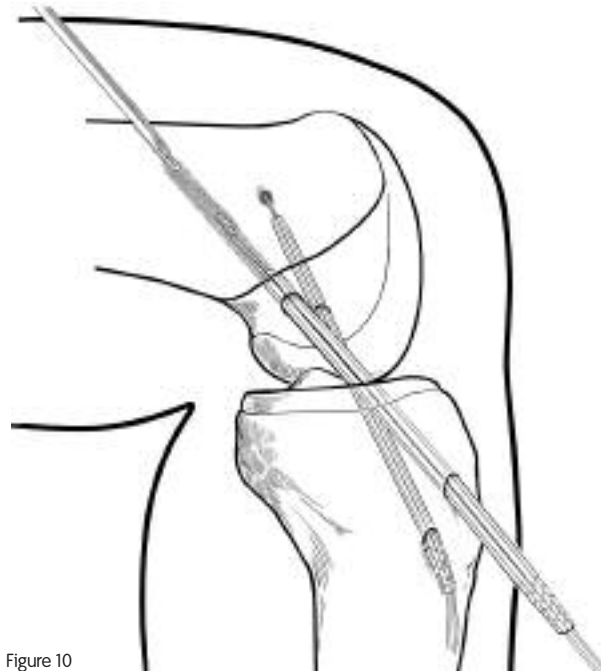


Figure 10

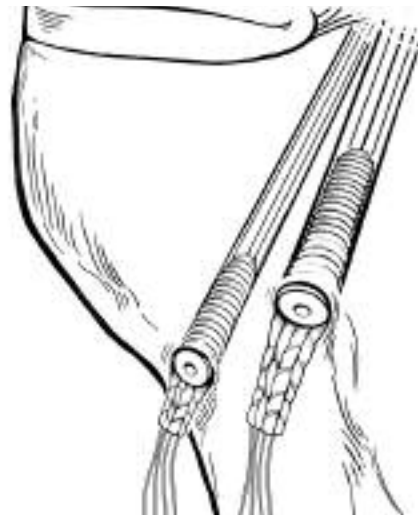


Figure 11

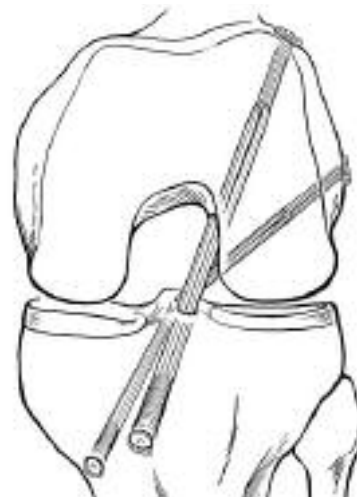

Figure 12

Additional Instruction

Prior to performing this technique, consult the Instructions for Use documentation provided with individual components — including indications, contraindications, warnings, cautions, and instructions.

Courtesy of Smith & Nephew, Inc.,
Endoscopy Division

Caution: U.S. Federal law restricts this device to sale by or on the order of a physician.